

Rare Case Report: Chondrosarcoma Arising from Osteochondroma in MHE patient.

Charles A Simanjuntak¹, SutiansiHartanta²

¹ Faculty of Medicine and Health Sciences, University of Jambi, Jambi

² General Practitioner, Jambi

Email : charliesjuntak@gmail.com

Introduction

Chondrosarcoma is the second most common bone sarcoma, accounting for around 20% of bone sarcomas in the United States.^{1,2} It arises mainly in patients over 40 years of age, has a slight male predominance and can be either primary or secondary to a previous benign chondral lesion such as an osteochondroma or an enchondroma. Histologic grading, proposed by Linchtenstein and Jaffe is intended to reflect the aggressiveness of the lesion with grade 1 tumors designated as low-grade and grades 2 and 3 as high-grade neoplasms.¹

MHE (Multiple Hereditary Exostoses) is an autosomal dominant skeletal disorder characterized by the presence of multiple osteochondromas with a prevalence of approximately 1 in 50.000 individuals.^{3,4} MHE is synonymous with HME (Hereditary Multiple Exostoses), Diaphyseal Aclasia and Multiple Osteochondromas (MO).^{5,6,7} The term "multiple exostoses" was given to the condition by Virchow in 1876.³ Approximately

15% of the osteochondroma patients have multiple lesions of which 62% have a positive family history.⁸ The risk of malignant progression has been estimated between 1 to 25% of patients with MHE.^{9,10}

Osteochondroma

(osteocartilaginous exostosis) is a cartilage capped bony projection arising on the external surface of bone containing a marrow cavity that is continuous with that of the underlying bone.^{9,11,12} Malignant transformation of Osteochondroma occurs mainly in the cartilaginous cap into low-grade chondrosarcomas. Low-grade chondrosarcomas tend to grow in the periphery, enlarging the cartilaginous cap, which produces the clinical alert signs and can be confirmed in MRI.¹³

Etiology

As with many cancers, the cause of chondrosarcoma is not clear. However, people with certain medical conditions have an increased risk for developing chondrosarcoma. These conditions include:

- Ollier's Disease
- Maffucci Syndrome
- MHE (Multiple Hereditary Exostoses)
- Wilm's Tumor
- Paget's Disease
- Diseases in children that required previous treatment with chemotherapy or radiation therapy.¹⁴

Incidence

Chondrosarcoma is a rare malignant tumor that produces cartilage matrix. The overall incidence of Chondrosarcoma is 1 in 200,000 per year, and it is the third most frequent malignant bone tumor after Multiple Myeloma and Osteosarcoma.^{15,16}

Primary Chondrosarcoma typically affects an old population. The majority of patients are older than 50 years old. The peak incidence is in the fifth to seventh decades of life. There is a male predilection of 1,5-2 to 1.¹⁶ Some of the newest literature suggest almost no gender differences in Chondrosarcoma.^{1,15}

Chondrosarcoma can involve any other bone; the incidence of axial and appendicular involvement is very similar. The bones of pelvis, especially for ilium are frequently involved. Long tubular bones are frequently affected. The proximal femur is the most preferred site, followed in frequency by proximal humerus, distal femur and ribs. Other less frequently involved bones are the spine, scapula and sternum. Chondrosarcoma rarely involves craniofacial

bones, neck, forearm, clavicle and sesamoids (including the patella). Chondrosarcoma in the small tubular bones is extremely rare (1-4% of all cases).^{15,16}

Symptoms

Clinical symptoms are mostly nonspecific. Localized pain is the most frequent presenting symptom (about 80%) after local swelling.^{14,16} The symptoms are usually insidious, progressive, worst at night and have a long duration (several months or years). Pathologic fractures are also common at initial presentation (up to 29%).² Restricted range of motion (ROM) is a common report of individuals with severe involvement of the proximal femur and forearm.^{3,7,12,14}

Signs

- A mass that can be felt (palpable).
- Broken bone (fracture).¹⁶

Imaging

Radiograph of conventional chondrosarcoma typically reveal a mixed lytic and sclerotic pattern with characteristic small calcifications, often referred as "popcorn" or "Ringlets" calcifications. Radiographic findings including cortical destruction, soft tissue extension and permeative pattern is often seen in high-grade tumors. Endosteal scalloping greater than two-third of the normal thickness of the long bones cortex is strong evidence of Chondrosarcoma over enchondroma.¹⁶

Magnetic Resonance Imaging (MRI) is a preferred modality in diagnosis of chondrosarcoma as well as in evaluation of the extent of marrow involvement and presence of soft tissue extension.¹⁶

Management

Chondrosarcomas (CHS) represent a heterogeneous group of disorders ranging from indolent, low-grade tumors to aggressive high-grade tumors. Surgical resection represents the primary and preferred treatment modality for individuals with localized disease.^{1,14,16,17,18} Radiation therapy is appropriate for the treatment of positive surgical margins or palliation of disease related symptoms. The treatment of advanced, metastatic disease is particularly challenging given the recognition that conventional chemotherapy has proven to be largely ineffective.^{2,17}

Complication

Great variation in biologic behavior between grades is characteristic of chondrosarcoma, ranging from a latent or slow-growing tumor to an aggressive sarcoma, with rapidly developing pulmonary metastasis. Low grade tumors usually have a more benign behavior, as well as a less aggressive aspect on imaging with no cortical expansion, destruction or soft tissue mass. High grade chondrosarcomas on the other hand typically exhibit all three.¹

Prognosis

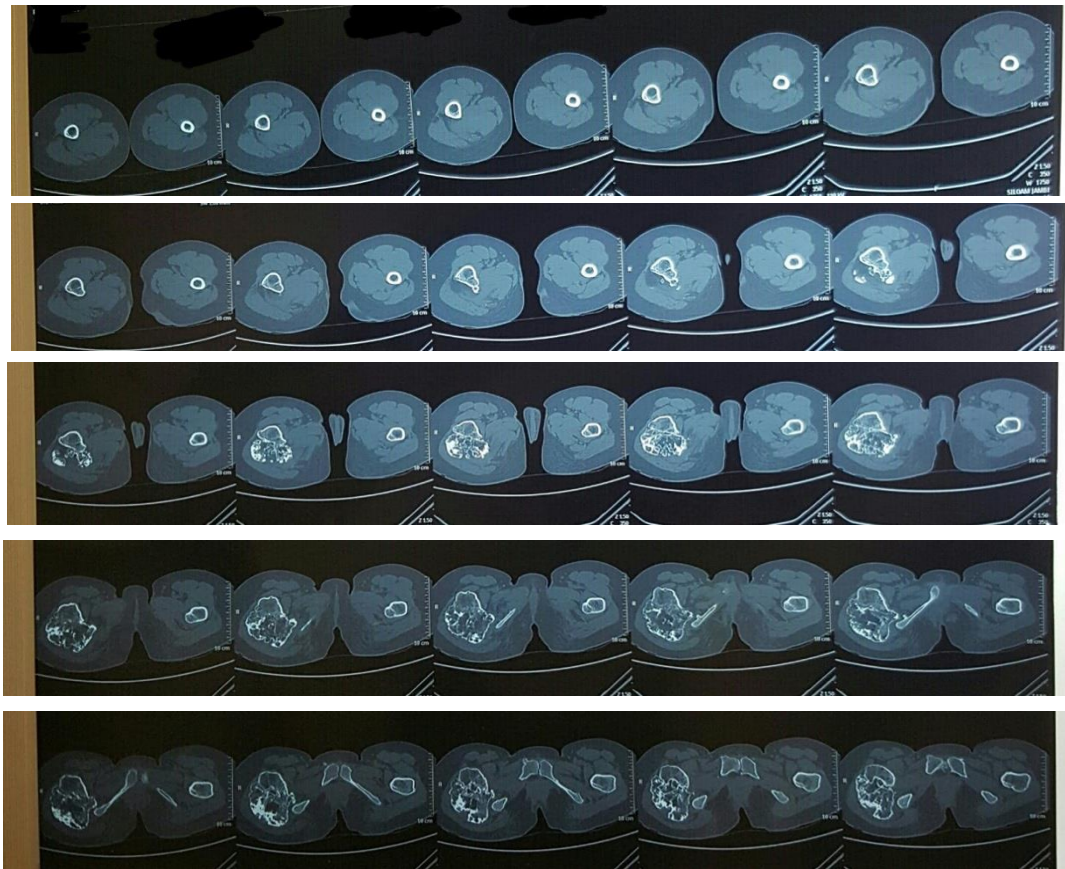There is no consensus on prognostic factors to determine which patients have a higher risk of treatment failure and disease related death.^{2,14,15} The outcome of patients with primary central chondrosarcoma of bone who present with localized disease is mostly affected by tumor.^{2,18} Patients with Grade 1 tumors have a 90% 5-year survival rate, whereas only 40% to 60% of patients with Grades 2 and 3 tumors will survive after 5 years. A recent population study suggested that patients who survive for ten years are more likely to die of events that were unrelated to chondrosarcoma.¹

Case Report:

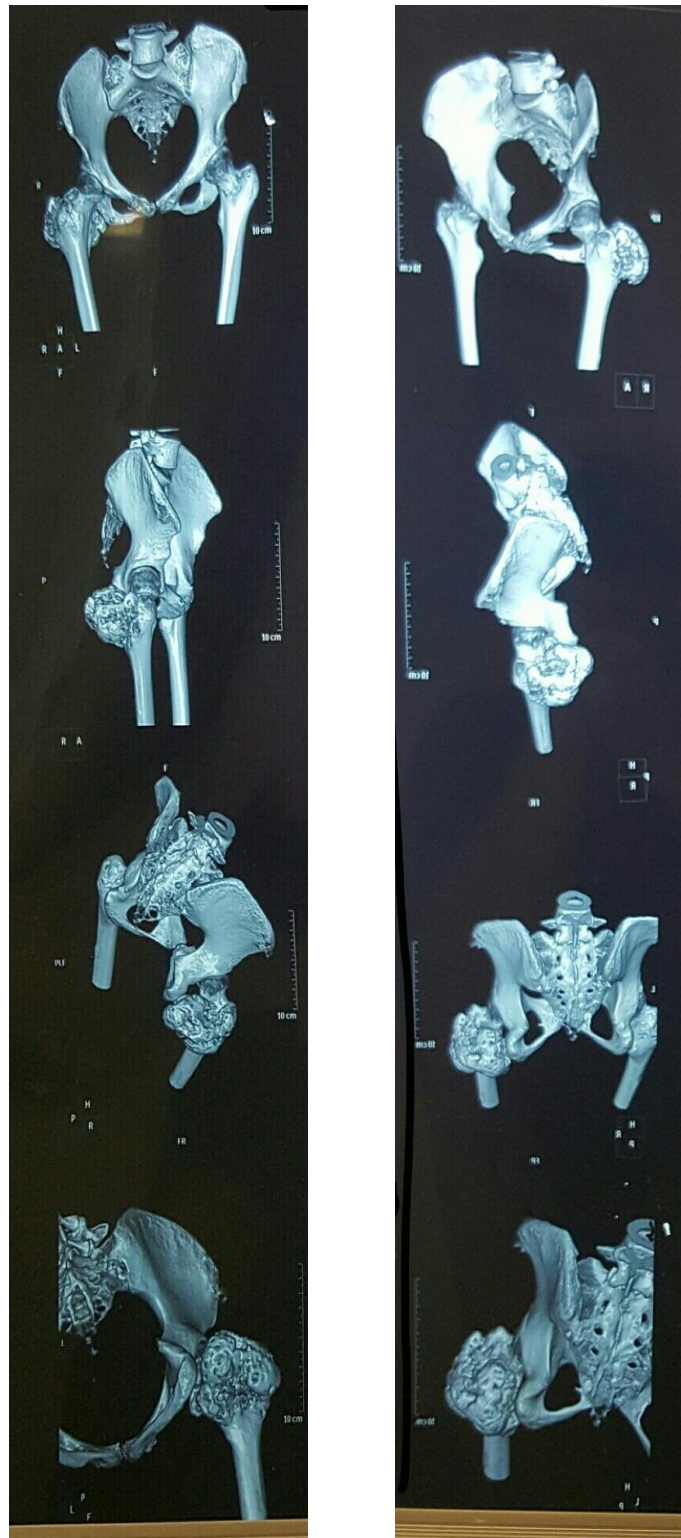A 26 years old woman came with a chief complain of the right hip had been uncomfortable since one year before. The uncomfortable feeling was worsened since 3 months ago, and sometimes made her feel tingling in her right hip after activity. The range of movement was not disturbed. She had no history of trauma, and the family history was unremarkable. She had been operated because of swelling in the left radius and was diagnosed chondrofibroma in the left radius about 10 years ago. The swelling was not developed again after it had been operated. At presentation, a large, firm, and slightly tender mass was palpated near the right trochanter major. The tissue mass seemed to be attached to the bone. Later she took CT scan for the uncomfortable

feeling in her right hip. The conclusion of the CT scan was osteochondroma. Later she took an open biopsy which was suggested by her orthopaedist, and again the result is osteochondroma. Because the lesion was highly suggestive of malignancy, the orthopaedist again recommend the patient to get a MRI for her bony mass. The result came with suspicion of high grade malignancy. She then assigned for a bone

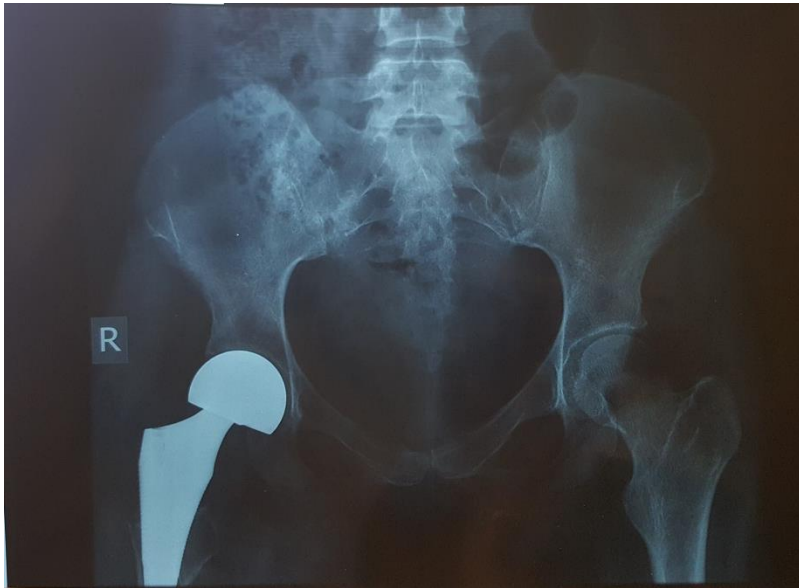
graft surgery, but during operation, the orthopaedist found out that the lump was so fragile, and was fractured during operation. Three weeks later, she was assigned again to get a total hip replacement surgery, which was continued by a 30 times of radiation. Now, the patient can have a quite normal daily activities although she cannot bend the right leg more than 90 degrees.



Picture 1. CT scan of pelvis (17/2/2015)



Picture 2. MRI of the pelvis (17/2/2015)



Picture 3. Pelvis AP after right total hip replacement (4/6/2015)

Discussion:

Chondrosarcoma is the second most common bone sarcoma, accounting for around 20% of bone sarcomas in the United States. It arises mainly in patients over 40 years of age, has a slight male predominance and can be either primary or secondary to a previous benign chondral lesion such as an osteochondroma or an enchondroma. Histologic grading, proposed by Linchtenstein and Jaffe is intended to reflect the aggressiveness of the lesion with grade 1 tumors designated as low-grade and grades 2 and 3 as high-grade neoplasms.

Osteochondromas are cartilage capped bony projections arising on the external surface of bone containing a marrow cavity that is continuous with that of the underlying bone. A diagnosis of MO can be made when

radiologically at least two osteochondromas of the epiphyseal region of the long bones are observed, in which this patient we found nine exostoses on her right and left knee. She also has a positive family history of her older sister who underwent a bone surgery.

Usually in osteochondroma, we have a male predominance of 1.5 : 1, with more recent studies of nuclear families demonstrating no evidence of gender predominance, in this case, both of the patients are women, and their parents didn't have a previous history of abortion. History of any bone lumps of their parents is doubtful. Her older sister has a previous history of bone surgery, and with more careful investigations, we found that her older sister also has a MHE that became chondrosarcoma on the right hip which was operated 1 year before, and also had a radiotherapy to cure the chondrosarcoma.

Clinical signs of malignant transformation include an increase in size of a lump and pain. The most important complication is malignant transformation of osteochondroma towards secondary peripheral chondrosarcoma, which is estimated to occur in 0,5 to 25%. The suspicion of secondary chondrosarcoma is indicated by growth of the tumor after puberty, the presence of pain, or a thickness over 1 cm of the cartilaginous cap in adults. That's why we suggest the patient to seek for medical attention if her lumps are painful and increasing in size.

Conclusion:

This is a unique case of chondrosarcoma. From this case, we learn that, Multiple

Hereditary Exostoses have strong connection with familial bond. This disease has male predominance, but in this case, the family don't have any son, and the father are healthy without any sign and symptoms of lumps. As a physicians, it is important to take careful examinations if a patient complain of any bony lump, then it is necessary to take careful and thorough examination of the patient's body, to know if there are other lumps in the patient's body, because the chances of getting malignant transformations are bigger in patients who have multiple exostoses, than from patient with single exostose.

References:

1. O. P. Camargo, A. M. Baptista, M. J. Atanasio, et all, "Chondrosarcoma of bone", *ClinOrthopRelat Res*, 468, 2969-2975, 2010.
2. D. Andreou, S. Ruppin, S. Fehlberg, et all "Survival and prognostic factors in Chondrosarcoma Results in 115 patients with long-term follow-up", *ActaOrtopaedica*, vol. 82, no. 6, 749-755, 2011.
3. J. R. Stieber, J. P. Dormans, "Manifestation of Hereditary Multiple Exostoses", *Journal of the American Academy Orthopaedic Surgeon*, vol 13, no 2, 110-120, 2005.
4. Y. Z. Wang, K. W. Park, C. S. Oh, et all, "Developmental pattern of hip in patients with Hereditary Multiple Exostoses", *BMC Musculoskeletal Disorders*, 2015.
5. OrthoInfo.org.2012.Osteochondroma.orthoinfo.aaos.org/topic.cfm?topic=A00079.25 Februari 2016.
6. Radiopaedia.org.2016.Hereditary multiple exostoses.radiopaedia.org/articles/hereditary-multiple-exostoses.25 Februari 2016.
7. J. Khurana, F. A. Karim, J. V. M. G. Bovee, "Pathology and Genetics of Tumours of Soft Tissue and Bone", *World Health Organization Classification of Tumours*, IARC Press, Lyon, 2002.
8. L. Hameetman, J. V. M. G. Bovee, A. H. M. Taminiou, et all, "Multiple Osteochondromas: Clinicopathological and Genetic Spectrum and Suggestions for Clinical Management", *Hereditary Cancer in Clinical Practice*, vol2, 161-173, 2004.

9. S. Tenenbaum, H. Arzi, N. Shabshin, B. Liberman, I. Caspi, "Selective Computerized Tomography – guided Perisciatic Injection as a Diagnostic Tool in MHE, *Healio Orthopedics*, Volume 35, issue 9, e1446-1448, 2012.
10. G. A. Schmale, D. C. Hawkins, J. Rutledge, and E. U. Conrad III, "Malignant Progression in Two Children with Multiple Osteochondromas", *Sarcoma*, vol. 2010, Article ID. 417105, 2010.
11. J. V. M. G. Bovee, "Multiple Osteochondromas", *Orphanet Journal of Rare Diseases*, Article ID 10.1186, 2008.
12. U. S. Keskar, S. A. Natu, "Hereditary Multiple Exostoses a case report", *Indian Journal of Applied Research, Pediatrics*, Volume 4, issue 10, 490-491, 2014.
13. E. E. Engel, M. H. N. Barbosa, M. S. Brassesco, et al, "Osteosarcoma arising from osteochondroma of the tibia: case report and cytogenetic findings", *Genetics and Molecular Research Journal*, vol. 11, 448-454, 2012.
14. J. V. M. G. Bovee, "Bone Tumors: Cartilage tumors, Chondrosarcoma", *Atlas of Genetics and Cytogenetics in Oncology and Haematology*, Atlas ID 5063, 2003.
15. A. Y. Giuffrida, J. E. Burgueno, L. G. Koniaris, et al, "Chondrosarcoma in the United States (1973 to 2003): An Analysis of 2890 Cases from the SEER Database", *Journal of Bone and Joint Bone Surgery. America*, vol. 91, pp. 1063-1072, 2009.
16. M. J. Kim, K. J. Cho, A. G. Ayala, J. Y. Ro, "Chondrosarcoma: With Updates on Molecular Genetics", *Sarcoma*, vol. 2011, Article ID. 405437, 2011.
17. R. F. Riedel, N. Larrier, L. Dodd, D. Kirsch, S. Martinez and B. E. Brigman, "The Clinical Management of Chondrosarcoma", *Current Treatment Options in Oncology*, Vol. 10(1), pp. 94-106, 2009.
18. K. Yokota, A. Sakamoto, Y. Matsumoto, et al, "Clinical Outcome for Patients with Dedifferentiated Chondrosarcoma: a report of 9 cases at a single institute", *Journal of Orthopaedic Surgery and Research*, DOI: 10.1186/1749-799X-7-38, 2012.